

The Outcome of One-Stage Surgery (Open Reduction, Femoral Osteotomy, Pelvic Osteotomy) in the Treatment of DDH Between 1.5 and 6.5 Years in Basrah

Mohamad A. Akber

Nursing college - University of Basrah, PhD. orthopedic senior. Lecturer

Email: mohammed.almayyahi@uobasrah.edu.iq

Abstract. Background: A broad range of hip developmental anomalies that may be identified at birth or develop later are included in developmental dysplasia of the hip (DDH). It involves a range of disease severity, from full hip dislocation to mild acetabular dysplasia. Methods: The study (prospective cohort) was performed at Ibn-Albetta Orthopedic Center. The period was between February 2019 to March 2024, patients with frank dislocation between 1.6 to 6.5 years were included. Exclusion criteria include those with a neuromuscular disorder, Arthrogryposis, failed previous surgery, and previous hip infection. Results: One hundred six patients were included (118 hips, 94 unilateral, and 24 bilateral), at the time of surgery the mean age was between 18 to 80 months, group A (61 hips) those less than 28 months while group B (57 hips) include those 28 months age and older. All hips underwent the same procedure which included single-stage open reduction, femoral osteotomy, and modified Salter osteotomy, and the mean follow-up was between 27-32 months. Regarding demographic data, the difference was for the age with the female and the left side most commonly affected. Conclusion: A single-stage operation consisting of open reduction, femoral osteotomy, and pelvic osteotomy yielded favorable radiological and clinical results for the treatment of DDH in patients between the ages of 1.5 and 6.5.

Highlights:

1. DDH ranges from mild dysplasia to severe hip dislocation.
2. Prospective cohort study of 118 hips (2019–2024); single-stage surgery.
3. Single-stage surgery showed favorable outcomes for DDH (ages 1.5–6.5).

Keywords: one-stage surgery, open reduction, femoral osteotomy, pelvic osteotomy, DDH

Introduction

Hip developmental abnormalities that may be identified at birth or develop later are all included in the broad category of developmental dysplasia of the hip (DDH). The disorder can range in severity from mild acetabular dysplasia to complete hip dislocation (1-4).

Depending on the patient's age and the severity of the condition, a number of DDH management options were introduced; however, when treating patients past walking

age, the surgeon faces challenges due to femoral anteversion, soft tissue obstructions, and chronic adaptive changes related to the acetabulum (5, 6).

Achieving and maintaining a concentric femoral head reduction inside the acetabulum is the primary goal of DDH therapy in order to support healthy hip growth. Although a variety of nonoperative and surgical techniques can accomplish this with satisfactory long-term results, treatment outcomes and ease are believed to be negatively correlated with age at presentation (2, 7–10).

Operational management options include femoral osteotomies (FO), pelvic osteotomies (PO), open reduction (OR) and capsulorrhaphy, or combinations of all three (2, 8, 11, 12). Nonetheless, the majority of surgeons favor carrying out a single-stage operation, particularly in children older than three years old. It includes pelvic osteotomy, open reduction, capsulorrhaphy, and, if required, a femoral osteotomy (shortening, derotation, or both) (6, 13–16). Particularly in those older than three, since the acetabulum's remodeling potential becomes unpredictable after this age (12, 17). Numerous studies have reported that the one-stage procedure yields satisfactory functional and radiological outcomes. Additionally, it reduces the financial burden, shortens hospital stays, and spares the kids from having to undergo numerous surgeries (13, 14). The main goal of the current study was to present our short-term results following a one-stage procedure for the surgical management of a group of patients with DDH. This therapy included open reduction, modified Salter or Dega pelvic osteotomy (DPO), and femoral osteotomy if necessary. Comparing the prevalence of functional, radiological, and other issues in patients under 30 months versus those above 30 months was the secondary goal

Methods

The study (prospective cohort) was performed at Ibn-Albetta Orthopedic Center. The period was between February 2019 to march 2024, patients with frank dislocation between 1.6 to 6.5 years were included. Exclusion criteria include those with a neuromuscular disorder, Arthrogryposis, failed previous surgery, and previous hip infection.

Preoperative assessments include history taken from the family about: Name, gender, perinatal history, and milestones to exclude neuromuscular disorders. All

patients underwent a general examination, spine and other joints exam, Hip range of movement, and limb length discrepancy.

Radiographic examination including anteroposterior (AP) X-ray of the pelvis and both hips to assess the Acetabular index (19) and Hip dislocation stage based on the Tonnis classification (18).

Surgical steps

All surgeries were performed by one specialist surgeon under general anesthesia and the patient was in a supine position with the availability of an image intensifier. After the patient becomes fully relaxed, we evaluate the hip assess reducibility and fix the patient on the table with plaster then painting and draping. Open reduction of the hip was done through the anterior (ilioinguinal incision), releasing the superolateral muscle attachment to the capsule, cutting the rectus and releasing the reflected head, and cutting iliopsoas tendon, after the capsule became full visualized capsulotomy was done through two incisions, one parallel to the edge of the true acetabulum and the other depends on the degree of dislocation some time vertical and sometime oblique to the first one. Then cutting and removing the ligamentum teres, cutting the transverse acetabular ligament, removing the pulvinar, and clearing the true acetabulum. Then the gentle trail of femoral head reduction, sometimes we can't reduce the femoral head in older children with high dislocation, The reduction benefit is to assess the anteversion of the femoral head inside the true acetabulum and assess tension of reduction, if the reduction is stable without tension with at least 5 mm telescoping and acceptable anteversion then open reduction alone is enough, if not then we make other incision at the lateral aspect of proximal femur exposing the bone and perform femoral osteotomy by using 2.7 dynamic compression plate, our method to assess how much shortening needed is to calculate the distance of femoral head that lie superior to the true acetabulum and cut the same distance from proximal femur aiming at least 5 mm telescoping, in rare cases we do proximal femur osteotomy to correct anteversion of femoral head only, but most of cases we need to do shortening.

After we close the femoral osteotomy wound, then we cut the redundant part of the hip capsule that lie at the superolateral aspect and start suturing the hip capsule with four suture techniques at the edge of the true acetabulum, two at medial side and two at lateral side, after that, we start doing pelvic osteotomy either modified Salter

(44,45) or Dega (6,20,21). Finally, after complete closure, we do one and a half hip spica cast.

Protocols for postoperative care and follow-up

Hip reduction was confirmed by an AP pelvic plain radiograph taken right after surgery. Typically, patients stay in the hospital for one day. In addition to cast care, we educate the mother on how to turn the kid and raise the lower limb with one pillow. After 15 days, follow-up appointments were planned for the cast care and wound assessment, as well as an x-ray to confirm hip reduction. The second appointment was for radiographic evaluation and cast removal at 45 days. After that, the patient begins physiotherapy, weight-bearing, and active mobilization. Following that, follow-up appointments were planned for six and twelve months, and then once a year.

outcomes evaluation

The difference in leg length was measured and a functional evaluation was performed using the Modified McKay's criterion (22). The Bucholz-Ogden classification system (25) and the Modified Severin grading system (23, 24) were used to evaluate radiographic findings for the presence of avascular necrosis (AVN) in the femoral head. Complications occurred at any time during the follow-up period. All patients were available for evaluation by the time of the last follow-up, when the radiological and functional evaluations were completed and reported. Patients less than 28 months were in Group A, and patients older than 28 months were in Group B.

Statistical test

Data analysis by using SPSS version 26.

Result and Discussion

The mean age of the 106 patients (118 hips, 94 unilateral, and 24 bilateral) at the time of surgery was between 18 and 80 months; group A (61 hips) consisted of those under 28 months, while group B (57 hips) consisted of those above 28 months. The identical treatment was performed on each hip, involving femoral osteotomy, modified Salter osteotomy, and single-stage open reduction. The average follow-up period was 27–32 months. Regarding demographic data, the difference was for the age with the female and the left side most commonly affected (Table 1). In terms of preoperative radiological and clinical evaluation, the two groups differed significantly in

terms of Tonnis grades (Table 3), Acetabular index (Table 2), and leg length disparity. Intraoperative data showed a substantial difference between the two groups, with group B exhibiting more femoral shortening and derotation, a longer operative time, and a lower telescoping distance (Table 4). At the last follow-up visit, the functional results were assessed using Modified McKay's criteria. The results showed that 114 hips had good outcomes (Excellent 48 hips, Good 66 hips), with notable variations between the two groups (Table 5).

Both groups experienced a considerable reduction in leg length discrepancy after surgery; however, group A's mean leg length was 1.95 mm, while group B's was 6.63 mm (Table 6). At the last follow-up visit, the radiological results were assessed using the Modified Severin grading system. The results showed that 114 hips (grade 1 70 hips and grade 2 44 hips) had good outcomes, with notable variations between the two groups (Table 5). Both groups experienced a considerable drop in their Acetabular Index after surgery; however, group A's mean was 19 degrees, whereas group B's was 22.4 degrees (Table 6). The Bucholz-Ogden classification system was used to evaluate avascular necrosis of the femoral head, and group B had a greater incidence (3 grade 1 in group A, 21 grade 1, and 2 grade 3 in group B). Table 7 displays each patient's specific issues.

Table 1

Demographic variables				
		age		Total
		Group	Group	
		A	B	
		<= 28	>28	
Numbers		61	57	118
Sex	M	13	14	27
	F	48	43	91
Operative side	R	27	24	51
	L	34	33	67
unilateral or bilateral	unilateral	53	41	94
	bilateral	8	16	24
follow up		27.08	31.72	
Total		61	57	118

Table 2

		PREOPERATIVE DATA				
	age	N	Mean	Std. Deviation	P – value	Sig.
LLD preoperative	Group A ≤ 28	61	9.62	2.099	0.00	S
	Group B >28	57	17.53	5.651		
Acetabular index preoperative	Group A ≤ 28	61	38.13	2.553	0.00	S
	Group B >28	57	44.11	4.337		

- T – test , P – value < 0.01 = significant (S) otherwise non-significant (Ns)

Table 3

PREOPERATIVE DATA, age * Tonnis grade Crosstabulation							
Chi square test							
		Tonnis grade			Total	Significant	
		grade 2	grade 3	grade 4		P – value	Sig.
age	<= 28	11 (18%)	28 (46%)	22 (36%)	61 (100)	0.00	S
	>28	1 (2%)	6 (10%)	50 (88%)	57 (100%)		
Total		12	34	72	118		

Table 4

INTRAOPERATIVE DATA				T – test		
	age	N	Mean	Std. Deviation	P – value	Sig.
Operative time	≤ 28	61	87.49	7.049	0.00	S
	>28	57	112.23	14.227		
Femoral derotation Osteotomy degree	≤ 28	61	16.52	12.908	0.00	S
	>28	57	27.72	10.224		

Femoral telescoping intraoperatively	<= 28	61	5.90	1.060	0.00	S
	>28	57	4.72	.559		
Femoral shortening	<= 28	61	6.92	3.712	0.00	S
	>28	57	15.54	4.859		

• T – test , P – value < 0.01 = significant (S) otherwise non-significant (Ns)

Table 5

Postoperative clinical and radiological outcome , N=118						
X ² – test						
		age		Total	P – value	Sig.
		<= 28	>28			
Clinical evaluation Modified McKay's criteria	Excellent	41 (67%)	7 (12%)	48	0/00	S
	good	20 (33%)	46 (81%)	66		
	fair	0	4 (7%)	4		
Radiologic evaluation Modified Severin grading system	grade 1	54 (89%)	16 (28%)	70	0/00	S
	grade 2	7 (11%)	37 (65%)	44		
	grade 3	0	4 (7%)	4		
Bucholz-Ogden classification system of AVN	no AVN	58 (95%)	34 (60%)	92	0/00	S
	grade 1	3 (5%)	21 (36%)	24		
	grade 3	0	2 (4%)	2		

Note: the total for every classification is 61 for group A (<= 28) and 57 for group B (>28).

Table 6

Postoperative LLD at final follow-up, Acetabular index at final follow-up,						
	age	N	Mean	Std. Deviation	P – value	Sig.
LLD at final follow-up	<= 28	61	1.95	3.985	0.00	S
	>28	57	6.63	4.639		
Acetabular index at final follow-up	<= 28	61	19.00	1.633	0.00	S
	>28	57	22.39	3.069		

Table 7

Complications		age		Total
		<= 28	>28	
Complications	NO Complications	55	44	99
	Hip stiffness	0	5	5
	Lengthen at operated side	3	0	3
	Stitch infection	2	0	2
	leg short	0	1	1
	Shortening at operated side	0	2	2
	External rotation of the limb	0	2	2
	Hip Subluxation	0	3	3
	Plate infection	1	0	1
Total		61	57	118

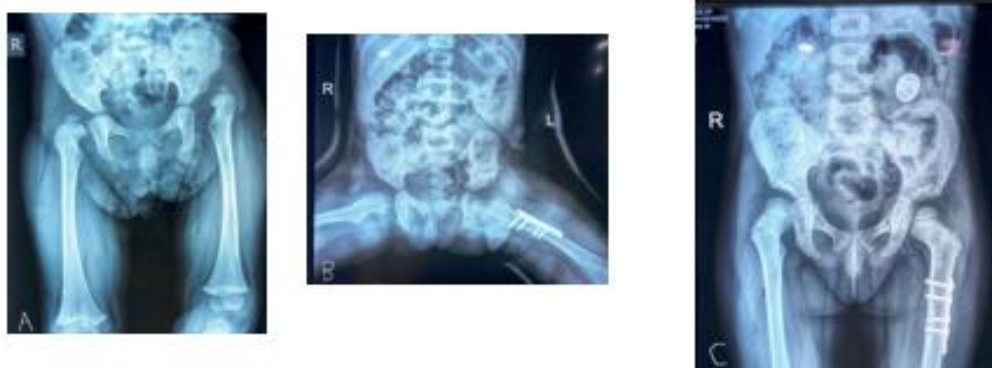

Fig 1: A. 24 months female with left side DDH, B. After six weeks at the time of cast removal C. After sixteen months

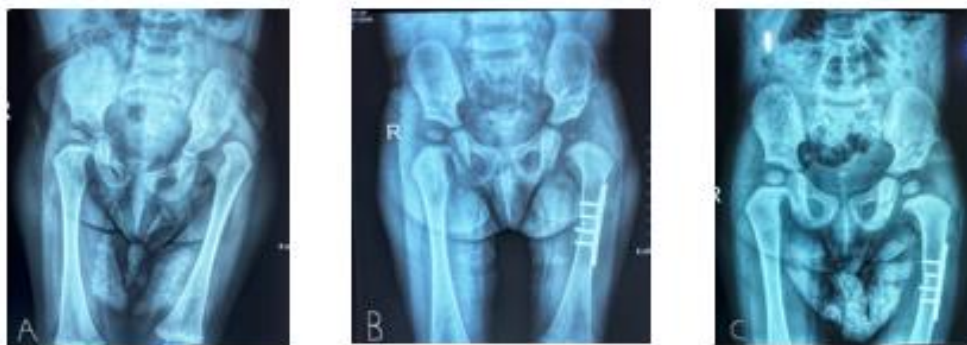

Fig 2: A. 20 months female with left side DDH with delay appearance of ossific nucleus, B. after three months C. After eighteen months

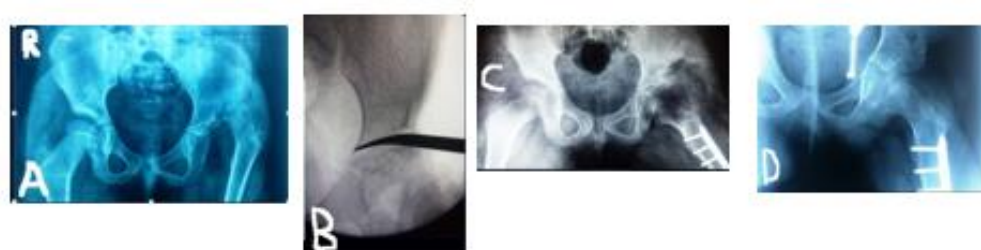


Fig3: A. Six 5.5 years old female with left side DDH, B. Intraoperative C-ARM image for Dega pelvic osteotomy C. After four months follow up. D. After thirteen months follow up.

Discussion

The current study found that most patients had satisfactory functional and radiological outcomes when they managed with a one-stage procedure that included OR, FDO, and PO. However, patients older than 28 months required longer operating times and experienced a higher rate of complications.

Children with developmental dysplasia of the hip (DDH) have a concentrated decline in acetabulum growth and development. Open reduction, with or without further osteotomies, is frequently necessary for congruous, stable reduction in children of walking age (7). If the femoral head kept moving outside of the acetabulum, it would cause certain anatomical alterations to the acetabulum and femoral head. The age at which hip reduction will lead to normal acetabular growth is unknown, although if the hip reduction is performed too soon, these changes might be reversible (8, 10).

Numerous authors proposed that acetabular development and growth could be satisfactorily achieved with a hip reduction by the age of four, and some even went so far as to extend it until the age of eight (15, 26). But the age at which DDH consider as a late presentation is debatable (8, 27)

Closed reduction has been shown to produce satisfactory results in some older children with or without adductor tenotomy as long as there is careful monitoring (9). Still, other research revealed that most After 18 months, individuals who had a successful closed reduction required another open procedure (32, 33). This is the reason why most surgeons consider OR for kids who couldn't do a concentric hip reduction with closed maneuvers or who were older than 12 to 18 months (10).

The majority of patients in a study by Charki et al. (34), which included 414 hips with DDH, had open reduction, pelvic osteotomy, and femoral osteotomy (42%); they suggested adding a femoral osteotomy for cases with high dislocation (Tönnis 3 or 4) and a pelvic osteotomy for children older than 36 months. A single-stage surgical strategy comprising an open reduction, pelvic osteotomy, and femoral osteotomy was recommended by certain surgeons (6, 10, 13). An acceptable result from a single stage operation eliminates the need for multiple stages surgical interventions. The majority of our study participants underwent single-stage operations that included open reduction, pelvic osteotomy, and femoral osteotomy because most of our patients have high dislocation (Tönnis grade 3 or 4), (82%) for group A and (98%) for group B.

Numerous pelvic osteotomies have been documented; the choice of one is based on the triradiate joint condition, patient age, and reduction concentricity (7, 11). In our study we use modified Salter osteotomy for group A, while for group B we use either modified Salter osteotomy or Dega pelvic osteotomy depend on patient age, femoral head converge and reduction concentricity and stability. Modified Salter osteotomy is good option for those less than 4 years. It is easy to perform, give good anterolateral coverage, and the use of pin fixation depends on hip stability and femoral head coverage intraoperatively (44,45)

Dega pelvic osteotomy combines the benefits of reorientation and reshaping of the acetabulum (35). Additionally, by modifying the osteotomy inner cortical cut (36,37), anterior or lateral coverage can be achieved. Due to the intact posteromedial cortical hinge and sciatic notch naturally caused osteotomy site recoil, no graft fxation was

required at the osteotomy site, and there were no need for fixation devices and complications of their removal (6,38).

Femoral derotation osteotomy is necessary if there is a problem with femoral anteversion, and femoral shortening is typically required if excessive force is needed for reducing the hip joint (33). All of the hips in our research had femoral osteotomy, either for derotation or shortening, and typically both. According to Czubak et al., femoral osteotomy was performed on every hip. However, according to a research by Ning et al. (13), all hips were shortened; however, a derotation was added in a subgroup of patients based on the degree of hip anteversion as assessed by a computed tomography (CT) scan performed prior to surgery. In order to evaluate the characteristics that indicated the necessity for a femoral osteotomy, Sankar et al. (39) looked at 72 hips with DDH.

In terms of functional results, Ning et al. (13) observed that 79.4% of patients had good or excellent functional outcomes. Our study's Modified McKay's criterion score is 40.7 Excellent and 55.9 Good. Zein et al. reported satisfactory outcomes 94.3% in group 1 (less than 30 months), 80.6 in group 2 (more than 30 months). (1) According to Czubak et al., 78.8% of their patients had satisfactory functional outcomes, and there was no difference between patients who were younger (group A) or older (group B) than three years [6]. Wozniak et al. conducted a systematic review (11). 84.8% of the hips' functional results were rated as good or very good during the most recent follow-up.

Our study's radiological results, which were evaluated indicated 59% grade 1 (excellent) and 37% grade 2 (good) using the Modified Severin grading system. Zein et al. reported radiographic results that were satisfactory (group I 94.3% versus group II 83.3%) in accordance with Severin radiological categories. (1), Ning et al. found that 84.7% of their patients had good or excellent radiological results (13). In addition Acetabular index have been corrected in our study from the preoperative mean of 38.13, 44.11 for group A, B respectively to 19 , 22.39 at final follow up. While Zein et al. obtained improvement from a mean of 37° to 27.2° at final follow up. According to Czubak et al., all patients' Acetabular index improved when compared to their preoperative values (group A's mean was 38.8° to 19.5°, while group B's was 39.6° to 21.3°), and the two groups' Acetabular indices at the last follow-up showed no differences. Wozniak and associates (11) systemic review reported an improvement in

Acetabular index; 16 studies reported a reduction to $< 20^\circ$, and the mean pre- and postoperative Acetabular index differed by 22.5° .

Avascular necrosis of the femoral head, which can happen up to 48% of the time and varies from research to study, is one of the most dangerous side effects that could happen after DDH surgery (7, 13, 41). In our study, we recorded 20% of patients with grade 1 and 2% of patients with grade 3 according to the Bucholz-Ogden categorization system. Zein et al. reported an AVN incidence of 5.6%, which only occurred in group II. A similar rate of 5.8% was recorded in the study by Czubak et al. (6). Ning et al. determined an incidence of 27.4% and classified them as bad outcomes based on the Kalamchi and MacEwen categorization (13). Wozniak et al. (11) calculated an AVN incidence of 18.9% based on 19 studies. There are limits to the existing study. A longer follow-up is required to demonstrate the effectiveness of the surgical strategy used in this investigation. Furthermore, in order to identify the factors impacting the occurrence of issues, we did not perform a correlation study..

Conclusion

For patients aged 1.5 to 6.5, a single step operation consisting of open reduction, femoral osteotomy, and pelvic osteotomy was used to treat DDH. The clinical and radiological outcomes were satisfactory

References

- [1]. B. Zein, A. A. Khalifa, M. E. Elsherif et al., "Are the Outcomes of Single-Stage Open Reduction and Dega Osteotomy the Same When Treating DDH in Patients Younger than 8 Years Old?" *Journal of Orthopaedics and Traumatology*, vol. 24, no. 1, p. 43, Aug. 2023, doi: 10.1186/s10195-023-00725-3.
- [2]. S. Yang, N. Zusman, E. Lieberman, and R. Y. Goldstein, "Developmental Dysplasia of the Hip," *Pediatrics*, 2019, doi: 10.1542/peds.2018-1147.
- [3]. J. Han and Y. Li, "Progress in Screening Strategies for Neonatal Developmental Dysplasia of the Hip," *Frontiers in Surgery*, vol. 9, p. 995949, 2022, doi: 10.3389/fsurg.2022.995949.
- [4]. H. Sacks, C. Pargas-Colina, and P. Castaneda, "Developmental Dysplasia of the Hip: Guide for the Pediatric Primary Care Provider," *Pediatric Annals*, vol. 51, no. 9, pp. e346–e352, Sep. 2022, doi: 10.3928/19382359-20220706-08.

- [5]. M. M. El-Sayed, M. Hegazy, N. M. Abdelatif, M. A. ElGebeily, T. ElSobky, and S. Nader, "Dega Osteotomy for the Management of Developmental Dysplasia of the Hip in Children Aged 2–8 Years: Results of 58 Consecutive Osteotomies After 13–25 Years of Follow-Up," *Journal of Children's Orthopaedics*, vol. 9, no. 3, pp. 191–198, 2015, doi: 10.1007/s11832-015-0665-9.
- [6]. J. Czubak, K. Kowalik, A. Kawalec, and M. Kwiatkowska, "Dega Pelvic Osteotomy: Indications, Results and Complications," *Journal of Children's Orthopaedics*, vol. 12, no. 4, pp. 342–348, Aug. 2018, doi: 10.1302/1863-2548.12.180091.
- [7]. S. Patwardhan, A. Madegowda, and P. Sancheti, "Evaluation of Acetabular Development Following Open Reduction of Developmental Dysplasia of Hip in Children After Walking Age," *Indian Journal of Orthopaedics*, vol. 55, no. 6, pp. 1583–1590, Sep. 2021, doi: 10.1007/s43465-021-00527-x.
- [8]. K. Venkatadass, V. Durga Prasad, N. M. M. Al Ahmadi, and S. Rajasekaran, "Pelvic Osteotomies in Hip Dysplasia: Why, When and How?" *EFORT Open Reviews*, vol. 7, no. 2, pp. 153–163, Feb. 2022, doi: 10.1530/EOR-21-0066.
- [9]. S. Barakat, A. B. Zein, A. S. Arafa, M. A. Azab, W. Reda, M. M. Hegazy, H. M. Al Barbary, and M. A. Kaddah, "Closed Reduction with or without Adductor Tenotomy for Developmental Dysplasia of the Hip Presenting at Walking Age," *Current Orthopaedic Practice*, vol. 28, no. 2, pp. 195–199, 2017, doi: 10.1097/BCO.0000000000000478.
- [10]. P. Kotlarsky, R. Haber, V. Bialik, and M. Eidelman, "Developmental Dysplasia of the Hip: What Has Changed in the Last 20 Years?" *World Journal of Orthopaedics*, vol. 6, no. 11, pp. 886–901, Nov. 2015, doi: 10.5312/wjo.v6.i11.886.
- [11]. H. H. Abdul-Ra'aoof, S. B. Dawood, F. A. Jassim, S. K. Jassim, S. S. Issa, M. A. Akber, and M. A. Atiyah, "Moderate Proficiency in Suture Techniques Among Nurses: A Cross-Sectional Study," **Journal of Nursing Education and Practice**, vol. 14, no. 2, pp. 50–58, 2024.
- [12]. C. Chunho, W. Ting-Ming, and N. K. Ken, "Pelvic Osteotomies for Developmental Dysplasia of the Hip," in **Developmental Diseases of the Hip**, D. S. Dusko, Ed. Rijeka, Croatia: IntechOpen, 2017, pp. Ch. 4. doi: 10.5772/67516. [Online]. Available: <https://www.intechopen.com/chapters/54481>

- [13]. E. H. Rahi, Z. M. Al-Hejaj, and A. M. Tiryag, "Nurses' Knowledge of Nonalcoholic Fatty Liver Disease: A Cross-Sectional Study," **Academia Open**, vol. 9, no. 1, pp. 10–21070, Jun. 2024.
- [14]. A. Bhatti, J. Kumar, and S. A. Butt, "Outcome of One Stage Combined Open Reduction, Pelvic and Derotation Femoral Osteotomy in Congenital Dislocated Hips of Children Younger Than Three Years Age," **JPMA Journal of the Pakistan Medical Association**, vol. 64, no. 9, pp. 1015–1020, 2014.
- [15]. A. M. Tiryag, "Revitalizing Hearts: The Transformative Impact of Pacemaker Therapy on Cardiac Conduction Disorders," **Academia Open**, vol. 9, no. 1, pp. 10–21070, Jun. 2024.
- [16]. H. Li, W. Ye, L. Xu, L. Li, W. Zhu, and Z. Zheng, "Sequential One-Stage Combined Procedure for Treating Bilateral Developmental Hip Dysplasia After Walking Age," **Journal of International Medical Research**, vol. 47, no. 7, pp. 2901–2909, 2019. doi: 10.1177/0300060519848943.
- [17]. F. A. Jassim, A. M. Tiryag, and S. S. Issa, "Effect of Bad Habits on the Growth of School Students: A Cross-Sectional Study," **Indonesian Journal on Health Science and Medicine**, vol. 1, no. 1, pp. 10–21070, Jul. 2024.
- [18]. D. Tonnis, "Normal Values of the Hip Joint for the Evaluation of X-Rays in Children and Adults," **Clinical Orthopaedics and Related Research**, vol. 119, pp. 39–47, 1976.
- [19]. M. A. Mohammad, F. A. Jassim, and A. M. Tiryag, "Single-Use Flexible Ureteroscope for the Treatment of Renal Stone," **Revista Latinoamericana de Hipertension**, vol. 18, no. 7, Dec. 2023.
- [20]. W. Dega, "Selection of Surgical Methods in the Treatment of Congenital Dislocation of the Hip in Children," **Chirurgia Narządów Ruchu i Ortopedia Polska**, vol. 34, no. 3, pp. 357–366, 1969.
- [21]. M. A. Mohammad, F. A. Jassim, and A. M. Tiryag, "Retrograde Intrarenal Lithotripsy Using Disposable Flexible Ureteroscope," **Georgian Medical News**, no. 348, pp. 44–46, Mar. 2024.
- [22]. V. R. Vallamshetla, E. Mughal, and J. N. O'Hara, "Congenital Dislocation of the Hip: A Re-Appraisal of the Upper Age Limit for Treatment," *Journal of Bone and Joint Surgery British Volume*, vol. 88, no. 8, pp. 1076–1081, Aug. 2006.

- [23]. M. A. Mohammad, A. Y. Al-Timary, and A. M. Tiryag, "Safety of Tubeless Double Access Percutaneous Nephrolithotomy Compared to Single Access Approach," *Bahrain Medical Bulletin*, vol. 45, no. 2, Jun. 2023.
- [24]. W. T. Ward, M. Vogt, J. S. Grudziak, Y. Tumer, P. C. Cook, and R. D. Fitch, "Severin Classification System for Evaluation of the Results of Operative Treatment of Congenital Dislocation of the Hip: A Study of Intraobserver and Interobserver Reliability," *Journal of Bone and Joint Surgery American Volume*, vol. 79, no. 5, pp. 656–663, 1997. doi: 10.2106/00004623-199705000-00004.
- [25]. K. M. Jassim, A. S. Khudhair, Z. S. Dawood, and A. M. Tiryag, "Nurses' Knowledge About Electrocardiogram Interpretation: A Cross-Sectional Study," *Rawal Medical Journal*, vol. 48, no. 4, p. 850, Oct. 2023.
- [26]. P. A. Gholve, J. M. Flynn, M. R. Garner, M. B. Millis, and Y. J. Kim, "Predictors for Secondary Procedures in Walking DDH," *Journal of Pediatric Orthopaedics*, vol. 32, no. 3, pp. 282–289, 2012. doi: 10.1097/BPO.0b013e31824b21a6.
- [27]. Z. S. Dawood, K. M. Jassim, A. M. Tiryag, and A. S. Khudhair, "Nurses' Knowledge and Attitudes Toward Deep Vein Thrombosis: A Cross-Sectional Study," *Bahrain Medical Bulletin*, vol. 45, no. 4, Dec. 2023.
- [28]. R. B. Salter, "Innominate Osteotomy in the Treatment of Congenital Dislocation and Subluxation of the Hip," *Journal of Bone and Joint Surgery British Volume*, vol. 43, no. 3, pp. 518–539, 1961.
- [29]. M. Jabbar, M. Mohammad, and A. Tiryag, "Changes in Male Reproductive Hormones in Patients With COVID-19," *Georgian Medical News*, vol. 342, pp. 42–46, Sep. 2023.
- [30]. H. Kitoh, H. Kaneko, and N. Ishiguro, "Radiographic Analysis of Movements of the Acetabulum and the Femoral Head After Salter Innominate Osteotomy," *Journal of Pediatric Orthopaedics*, vol. 29, no. 8, pp. 879–884, 2009. doi: 10.1097/BPO.0b013e3181c1e314.
- [31]. M. A. Mohammad, H. H. Abdul-Ra'aoof, R. M. KA, and A. M. Tiryag, "Parents' Knowledge and Attitudes Toward Testicular Torsion," *Bahrain Medical Bulletin*, vol. 46, no. 1, Mar. 2024.
- [32]. P. L. Schoenecker, P. A. Dollard, J. J. Sheridan, and W. B. Strecker, "Closed Reduction of Developmental Dislocation of the Hip in Children Older Than 18

- Months," *Journal of Pediatric Orthopaedics*, vol. 15, no. 6, pp. 763–767, 1995. doi: 10.1097/01241398-199511000-00008.
- [33]. H. M. Sabty, S. B. Dawood, and A. M. Tiryag, "Nurses' Knowledge and Practices on Influenza Vaccination for Pregnant Women," *Jurnal Kebidanan Midwiferia*, vol. 10, no. 2, pp. 50–59, Oct. 2024.
- [34]. M. Tazi Charki, H. Abdellaoui, K. Atarraf, and M. A. Aff, "Surgical Treatment of Developmental Dysplasia of the Hip in Children: A Monocentric Study About 414 Hips," *SICOT Journal*, vol. 8, p. 29, 2022. doi: 10.1051/sicotj/2022030.
- [35]. M. F. Hasan, W. F. Hussein, A. M. Tiryag, I. J. Ali, and Z. M. Shaker, "Nurses' Knowledge Toward Lower Back Pain: A Cross-Sectional Study," *Academia Open*, vol. 9, no. 1, Jun. 2024. doi: 10-21070.
- [36]. Y. C. Li, K. W. Wu, S. C. Huang, T. M. Wang, and K. N. Kuo, "Modified Triple Innominate Osteotomy for Acetabular Dysplasia: For Better Femoral Head Medialization and Coverage," *Journal of Pediatric Orthopaedics B*, vol. 21, no. 3, pp. 193–199, 2012. doi: 10.1097/BPB.0b013e32834f4377.
- [37]. A. A. Al-Iedan, M. A. Akber, S. B. Dawood, A. I. Alobaidi, S. S. Issa, H. H. Ra'aoof, Z. A. Khalaf, and A. M. Tiryag, "Bridging the Gap: Enhancing Open Fracture Care in Emergency Nursing," *Academia Open*, vol. 9, no. 1, Jun. 2024. doi: 10-21070.
- [38]. N. Ezirmik and K. Yildiz, "A Study on the Complications of Surgical Treatment for Bilateral Developmental Dysplasia of the Hip and a Comparison of Two Osteotomy Techniques," *European Journal of Medicine*, vol. 43, no. 3, pp. 162–168, 2011. doi: 10.5152/eajm.2011.38.
- [39]. M. A. Akber, A. M. Tiryag, and A. I. Alobaidi, "Nurses' Knowledge Concerning Developmental Dysplasia of the Hip: A Cross-Sectional Study," *American Journal of Pediatric Medicine and Health Sciences*, vol. 2, no. 4, pp. 155–160, 2024.
- [40]. P. Castañeda, L. Moscona, and K. Masrouha, "The Effect of Femoral Shortening in the Treatment of Developmental Dysplasia of the Hip After Walking Age," *Journal of Child Orthopaedics*, vol. 13, no. 4, pp. 371–376, 2019. doi: 10.1302/1863-2548.13.190029.
- [41]. A. Kothari, G. Grammatopoulos, S. Hopewell, and T. Theologis, "How Does Bony Surgery Affect Results of Anterior Open Reduction in Walking-Age Children With

Developmental Hip Dysplasia?" *Clinical Orthopaedics and Related Research*, vol. 474, no. 5, pp. 1199–1208, 2016. doi: 10.1007/s11999-015-4598-x.

- [42]. M. A. Akber, A. M. Tiryag, and A. I. Alobaidi, "Nurses' Knowledge Regarding Cast Complications of Limb Fractures: A Cross-Sectional Study," *Central Asian Journal of Medical and Natural Science*, vol. 5, no. 2, pp. 195–200, Apr. 2024.
- [43]. P. L. Schoenecker and W. B. Strecker, "Congenital Dislocation of the Hip in Children: Comparison of the Effects of Femoral Shortening and Skeletal Traction in Treatment," *Journal of Bone and Joint Surgery American Volume*, vol. 66, no. 1, pp. 21–27, 1984.
- [44]. H. H. Abdul-Ra'aoof, M. A. Akber, F. A. Jassim, A. M. Tiryag, S. S. Issa, M. A. Atiyah, J. A. Mezail, and I. S. Hassan, "The Psychological Impact of Violence on Emergency Department and Intensive Care Unit Nurses: A Cross-Sectional Study," *Research Journal of Trauma and Disability Studies*, vol. 3, no. 4, pp. 228–233, Apr. 2024.
- [45]. V. Suvorov and V. Filipchuk, "Modified Salter Osteotomy for the DDH Treatment," *Acta Ortopedica Brasileira*, vol. 31, no. spe1, p. e259040, Apr. 2023. doi: 10.1590/1413-785220233101e259040.